

PARTICIPANT STATISTICS

BODY FLUIDS MICROSCOPY

THIRD QUADRIMESTER 2016

Result	Labs	Flagging
White Blood Cells	3	
Total Population	3	

Intended result: WBC

Photo 1: Wright's Stain - High Oil

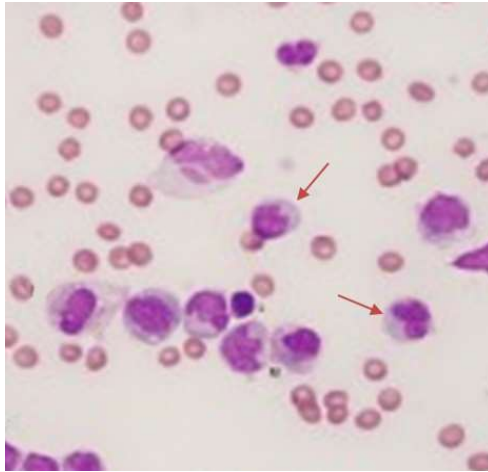
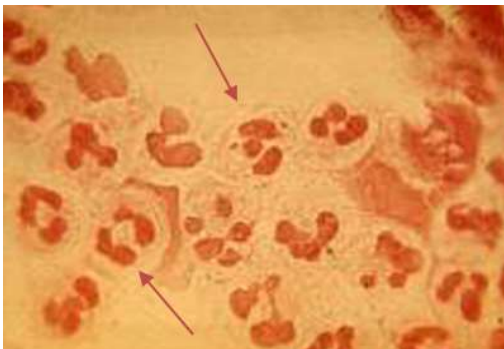


Photo 2: Gram Stain following centrifugation - High Oil



HOT SWOLLEN ELBOW 3RDQ 2016

A 45 year old male was seen in the doctor's office. He complained of pain while moving his right elbow. The joint was swollen and did not move freely on manipulation

Synovial fluid was removed from the joint and submitted for microscopic exam.